

KNEE

When screening patient, ask these questions and add to screening from notes. Tech will add to study notes:

- did you injure your knee? If so when?
- Was there surgery on this knee? If so, did they remove cartilage/meniscus?

1. 3 Pl Loc ****Image****
2. Sag PD—Include all bone through ligaments (Obl to condyles)
3. Sag T2 cl fat
4. Ax T2 cl fat- 4cm above patella through tib/fib joint
5. Cor PD—If protocol Knee Pain/Menisci/Ligaments or Synovitis
Cor T1—If protocol Knee AVN/OCD/FX
6. Cor PD cl fat—Popliteal Artery through patella
#7---Eastpark, SMC1, SMC2, OSP1, MR4 or if Coil doesn't allow acceleration
7. Obl Ax PD cl FAT Through Meniscus
#8 3T and ARTIST Scanners (except for Eastpark, which runs #7)
8. Sag PD CUBE Fat (Obl to condyles)
Ax, Sag, Cor reformats sent to **ALI STORE**

Synovitis (ensure to include pre Cor PD above and cover skin to skin on all sequences):
10. Pre Ax T1 FAT 11. +C Ax T1 Fat 12. +C Sag T1 Fat
**** METAL--SCAN Routine Knee (keep FAT SAT on), but add an additional Sagittal STIR**
*****If patient has a Knee Replacement—on Artist Scanners there is a Knee Replacement w/ MAVRIC protocol—Ok to run this when patients have a Knee Replacement—Ax STIR, Sag PD, Sag MAVRIC Fluid, Cor PD MAVRIC, Cor STIR**

Request:
MRI Knee wo or MRI Knee wo/w

USE 8 or 16 ch knee coil when possible
Opt 2: 16 ch wrap coil

Opt Contrast:
Vueway
0.05mmol/kg
Max 10

Low eGFR inpatient Dose: No Change

Knee Osteo/Abscess or Thigh/Calf w/o or Osteo/Abscess

****Try to get one slice down middle of bone**
****If there is a small ROI (tumor, mass, or area of pain) decrease FOV after large FOV COR STIR. Ensure to use thinner Axial Slices (5/1) to ensure area of interest is adequately covered. Call radiologist to check if questions****

1. 3 Pl loc **► SKIN TO SKIN**
2. Cor T1
3. Cor FSTIR (Knee—Cor T2 Fat)
4. Sag T1
5. Sag FSTIR (Knee—Sag T2 Fat)
6. Ax T1
7. Ax T2 Fat (**upr and lwr stack for long bones**)
►Thigh or calf Axial scans: (5/1.5 or 7/3 as needed)
8. +c Cor T1 Fat
9. +c Sag T1 Fat
10. +c Ax T1 Fat (**upr and lwr stack for long bones**)
►Metal /poor fat sat: for Ax T2 FAT substitute STIR or T2 No FAT. For T1 FAT substitute T1 Lava-Flex from Tumor protocol

Request:
MRI wo or w/w

►Thigh
►Calf
►Knee

Contrast:
Vueway
0.05mmol/kg
Max 10

Low eGFR inpatient Dose: No Change

HAMSTRING or QUADRICEPS INJURY

- Place marker at max pain or at upper & lower limits**
►Prox injury: Prox 2/3 thigh → above ischial tuberosity
►Distal injury: Distal 2/3 thigh→below knee, incl prox tibia
1. 3 Pl loc
 2. Cor T1 (5/1.5)
 3. Cor T2 dk fat
 4. Sag T1 (5/1.5)
 5. Sag T2 dk fat
 6. Ax T1 (5/1.5 or 7/2 as needed)
 7. Ax T2 dk fat

Request:
MRI Thigh wo

Coil:
8 Ch or 12 Ch Body array

QUICK TIBIA (FOR SHIN SPINTS ONLY)

1. 3 Pl loc **► MARKER ON POINT OF MAXIMAL PAIN**
2. Sag SSFSE (24 fov) Center on single marker
3. Ax T2 fat (5/2.5 16 fov) 32 slices with the center slice on marker

NEUROGRAM (See Lower Ext Neurogram instruction sheet)

MSK TIPS:

- Ensure extremity of interest is as isocenter as possible
 - SHIM all Fat sat scans!!
 - Use Smallest coil possible to ensure coverage for anatomy
- Include in Study notes: Date of injury? Previous surgery?**

TIBIAL STRESS FRACTURE

- Place marker at max pain or at upper & lower limits.**
1. 3 Pl loc ****center over area of pain****
 2. Sag FSTIR (4/4) ****IMAGES****
 3. Ax T1 (3/1.5) ****cover through area of pain/pathology****
► if patient has pain through the entire tibia or cannot localize pain instead of 3/1.5, run Axials at 5/1
 4. Ax T2 dk fat (3/1.5)
 5. Long Axis T1 Perpendicular to edema (3/0) (see images)
 6. Long Axis T2 dk fat Perpendicular to edema (3/0)
►If edema cannot be seen, oblique sagittally to tib/fib

Request:
MRI Calf w/o

Coil:
8 ch Cardiac
Gems:
30 Small

THIGH OR CALF

(Not for hamstring injury, Quadriceps tear, or Tibial stress FX)

- Place marker at max pain or at upper & lower limits**
1. 3 Pl loc
 2. & 3. Cor T1 & Cor T2 STIR (5/2) Joint to Joint
 4. & 5. Sag T1 & Sag T2 STIR (5/2) Joint to Joint
 6. & 7. Ax T1 & Ax T2 dk fat (5/1.5 or 7/3 as needed)

Request:
MRI Calf or Thigh wo

Hip, Thigh, Knee or Calf Tumor less than 8vo

- **Try to get one slice down middle of Femur or Tibia**
****Mark scar, lump, or mass and center FOV on ROI. No need to cover a joint. Only cover area of interest.**
****Don't need Skin to Skin on both Cor and Sag.**
****Must cover all pathology (OK to increase FOV to cover pathology).**
****Thigh/Calf: If there isn't a mass or certain area of interest, just pain "everywhere" then we can increase FOV and cover joint to joint.**
Call Rad with questions
1. 3 Pl loc
 2. Cor T1
 3. Cor FSTIR (Knee—Cor T2 Fat)
 4. Sag T1
 5. Sag FSTIR (Knee—Sag T2 Fat)
 6. Ax T1 (5/1)
 7. Ax T2 dk fat
 8. PRE AX T1 FAT (1 nex-ok if grainy)
 9. +c Cor T1 dk fat
 10. +c Sag T1 dk fat
 11. +c Ax T1 dk fat

Request:
MRI w/w

►Hip
►Thigh
►Calf
►Knee

Contrast:
Vueway
0.05mmol/kg
Max 10

Low eGFR inpatient Dose: No Change
****Images****

Thigh, Knee, or Calf Tumor (new!! Power Injection!!)

- **Try to get one slice down middle of Femur or Tibia**
****Mark scar, lump, or mass and center FOV on ROI. No need to cover a joint. Only cover area of interest.**
****Don't need Skin to Skin on both Cor and Sag.**
****Must cover all pathology (OK to increase FOV to cover pathology).**
****If there isn't a mass or certain area of interest, just pain "everywhere" then we can increase FOV and cover joint to joint.**
Call Rad with questions
1. 3 Pl loc
 2. Cor T1 (Knee 16FOV, Thigh/Calf 20 FOV 4/1)
 3. Cor FSTIR (Knee—Cor T2 Fat)
 4. Sag FSTIR (Knee—Sag T2 Fat) (Knee 16FOV, Thigh/Calf 20 FOV 4/1)
 5. Ax T2 Fat (5/1)
 6. Ax T1
 7. Ax T1 Lava-Flex Pre (In and Out of Phase to SOURCE)
---After Pre—ensure to Manual prescan and select done, this will ensure subtractions are accurate!
 8. Ax T1 Lava-Flex 2 min **►Prep scan inject and start timer, start scan at 2min**
 9. Cor T1 Lava-Flex
 10. Sag T1 Lava-Flex
 11. +c Ax T1 Fat
- **Subtract Pre Ax Lava-Flex from Post Ax Lava Flex—send to ALI STORE**
►Metal: If Tumor is adjacent to metal implant, send Pre Ax T1 Lava-Flex and call RR to see if they want to do T1 Post without FS instead of 3d Flex with subtraction (T1 post-T1 pre). Ax T2 FAT substitute STIR or T2 No FAT.

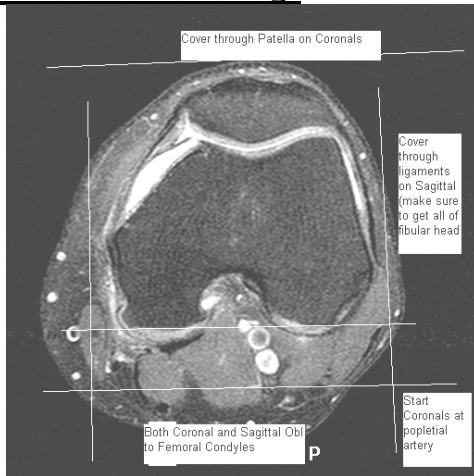
Request:
MRI w/w

►Thigh
►Calf
►Knee

POWER INJECTION @ 2ml/sec
Contrast:
Vueway
0.05mmol/kg
Max 10

Low eGFR inpatient Dose: No Change
****Images****

Routine Knee Coverage



Tibial Stress FX Instructions:

3 Examples of areas of edema

Step 1. Sag STIR look for bright areas of edema

Step 2. Ax T2 look for bright areas of edema

Example 1	Example 2	Example 3
<p>Periosteal reaction Outside edge of bone</p>	<p>Muscle tear Soft tissue</p>	<p>Stress Fx Within bone</p>

Step 3. Determine direction of edema

Example 1	Example 2	Example 3
		<p>??? direction</p>

Step 4. GRx slices long axis perpendicular to edema

Example 1	Example 2	Example 3
<p>Periosteal reaction tibia Scan thru tibia & fibula planes if unsure</p>	<p>Muscle tear Scan thru entire leg</p>	<p>Stress Fx within Scan in both Sagittal and Coronal</p>

Back to Protocol

Tumor and Osteo protocols:

Ensure to have one slice down the center of the Tibia or Femur:

