

## Division of Nuclear Medicine Procedure / Protocol University Hospital and The American Center

HEPATOBIILIARY IMAGING  
UPDATED: JULY 2017

CPT CODE: 78223

### Indications:

- Diagnosis of acute cholecystitis (both calculus and acalculous disease)
- Determination of patency of common bile duct when ultrasound examination not diagnostic (e.g., very early obstruction)
- Evaluation of biliary dyskinesia (gallbladder ejection fraction [GBEF] test) for chronic cholecystitis
- Identification of biliary leaks
- Differentiation of biliary atresia from neonatal hepatitis
- Evaluation of presence, or absence of, spleen (with T-99m SC Liver Scan).
- Suspected sphincter of Oddi dysfunction or partial biliary obstruction due to stones or stricture.

### Patient Preps:

#### Acute Cholecystitis

See Acute Cholecystitis algorithm below, Appendix 2

#### No Pre-Treatment:

- Fasting for a minimum of 2 hours, but preferably 4 hours before this test.
- Parental alimentation (ex. TPN) is allowable and considered to be a fasting state.

#### Pre-Treatment:

- Record any recent hydromorphone (Dilaudid), fentanyl, or morphine used in last 12 hours; refer to morphine use section below and opioid table in Appendix 1.
- In patients who have fasted for greater than 24 hours, on parenteral nutrition, or with a history of alcoholic liver disease, Sincalide (Kinevac) should be administered prior to tracer injection. Sincalide administration of 0.02 microgram/kg is to be over 30 min. Mebrofenin injection can be started 10-60 min after Sincalide infusion is completed. On-call cases of fasting state for pre-treatment sincalide administration should be determined by the technologist with the patient's nurse (*\*\*If there is any question or lack of information of fasting state, sincalide pre-treatment should be administered prior to imaging to clear the gallbladder.\*\**)
- In case of sincalide shortage, consider ensure PO pre-treatment prior to fasting as tolerated and allowed by the referring clinician

#### Sphincter of Oddi Dysfunction (SOD):

- Fasting for minimum of 2 hours. Patients should not have had any opiate drug (hydromorphone, fentanyl or morphine) within 6 hours; refer to opioid table in Appendix 1 for adjustments to the 6 hours.
- Patients then should be pretreated with Sincalide (Kinevac) at a rate of 0.02 microgram/kg over 30 minutes.
- Mebrofenin injection can be started 15-60 min post Sincalide infusion.

#### Gall Bladder Ejection Fraction

- Fasting for a minimum of 2 hours, but preferably 4 hours before this test.
- Patients should not have had any opiate drug (hydromorphone, fentanyl or morphine) within 6 hours; refer to opioid table in Appendix 1 for adjustments to the 6 hours.

## Division of Nuclear Medicine Procedure / Protocol University Hospital and The American Center

### Infant: neonatal hepatitis vs biliary atresia

To differentiate between neonatal hepatitis and biliary atresia pre-treatment with Phenobarbital, 5 mg/kg/day given orally in two (2) divided doses for 3-5 days, or ursodeoxycholic salt, 20 mg/kg/day 2-3 days, if needed to increase hepatocyte function, at ordering providers discretion. If patient is already on either of these medications and dosage, no pre-treatment is needed.

### **Protocol/Prep Modifications:**

#### If Total bilirubin >10 (within the last week)

Consult with the Nuclear Medicine Physician, a 1.5 to 2-fold increase in dosage may be prescribed and a longer imaging time requested.

#### Critically ill patients with sepsis

Require a IV Sincalide administration of 0.02 microgram/kg is to be over 30 min prior to scan and possibly larger doses of morphine (0.08 mg/kg) (especially when acute acalculous cholecystitis) (requires faculty approval) with more delayed images (30-40 min post morphine). If the patient is on gastric tube feedings, Sincalide is unnecessary. If tube feeding is into the proximal small bowel then Sincalide pre-treatment is required.

### **Scheduling:**

Acute Cholecystitis, Leak or Biliary Atresia: Allow 90 min of camera time. Delayed images are at 2 hours and 3-4 hours post-injection. Imaging 24 hours post-injection is possible.

#### GBEF:

Injection: allow 15 min.

Scan: Image 45 min post injection, allow 90 min camera time.

Modified Protocols: If pre-treatment is required account for the additional 30 minute infusion time. Then schedule as above for acute cholecystitis.

#### Sphincter of Oddi Dysfunction (SOD):

Pre-Treatment: Infusion of Sincalide over 30 minutes.

Injection: 15-60 minutes after completion of Sincalide begin imaging for 60 min. Allow 90 minutes of camera time. Delayed images are not typically needed.

### **Radiopharmaceutical & Dose:**

99mTc-Mebrofenin 5 mCi +/- 20% (4-6 mCi) IV, adjusted for weight per nomogram.

If patient is jaundiced (bilirubin > 10): NM physician should be consulted prior to dosing 99mTc-Mebrofenin to determine possible increase in dose (1.5-2 times) and/or adjustment of imaging times.

Sincalide 0.02 microgram/kg IV diluted with NaCl to 50 ml and infused over 30 minutes as a pre-treatment and over 60 minutes when for GBEF.

#### Sincalide (Kinevac) Preparation (Gallbladder EF):

- Reconstitution: Add 5 ml of sterile water to Kinevac vial containing 5 microgram to create a solution of 1 microgram/ml.
- Dose Preparation: Obtain patient's weight in kg and calculate dose at 0.02 microgram/kg. Withdraw dosage from vial and add to a 60 ml syringe loaded with 0.9% NaCl. Total volume with Kinevac and NaCl to be 50 ml. Dose is stable for 1 hour post-dilution of saline.
- Infusion Pump: Attach extension tubing to 60 ml syringe of Kinevac and place in infusion pump. Set up pump as single dose, B-D syringe, 50 ml dose for 60 min.

## Division of Nuclear Medicine Procedure / Protocol University Hospital and The American Center

### Morphine Use in Hepatobiliary Scans:

- Morphine 0.04 milligram/kg IV when indicated per protocol.
- Confirm patient is not allergic to morphine.
- Record any hydromorphone (Demerol), fentanyl, or morphine used in last 12 hours. If the patient is on opioids (within 5 half-lives - refer to **OPIOID REFERENCE TABLE** below (Appendix 1), get approval from referring clinician regarding approval to administer morphine for hepatobiliary scan.
- If the patient is an outpatient confirm they have a designated driver.
- The use of intravenous Morphine (0.04mg/kg to a max of 4 mg) is used as part of the functional assessment of the gallbladder in the hepatobiliary scan protocol. The hepatobiliary scan protocol includes the use of IV Morphine to elevate the pressure in the extrahepatic bile duct system and so fill the gallbladder. This has been established to improve the sensitivity and specificity of diagnosing acute cholecystitis.
- The section of nuclear medicine has used this Morphine-augmented protocol for 15 years without a single incident, and never had to inject a reversal agent.
- This sectional protocol establishes that the Hospital-wide conscious sedation does not apply to this diagnostic test (just as it does not apply to pain relief use of narcotics). The protocol does require a physician be available to supervise the administration of the Morphine, but this physician does not need to be credentialed for conscious sedation.

### PROCEDURE WHEN USING MORPHINE FOR PATIENT EXAMS:

- Fill out the sign-out form that is kept in the safe with the morphine.
- Do NOT fill out the pharmacy charge form.
- Morphine is supplied 4 mg/ml at 1.0 ml. Morphine that is NOT used for the exam must be disposed of and accounted for. This must be witnessed by another person, disposed of, and initialed by both parties.
- Update balance sheet with patient name and data.
- Return paperwork to safe, and lock.

**NOTE:** If the dose of Morphine is more than 4.0 milligram, **CONSULT WITH STAFF BEFORE INFUSION.**

### **Imaging Device:**

GE Infinia, Optima, Millennium VG or Millennium MPS gamma camera with LEHR collimator.

### **Imaging Procedure:**

#### Acute Cholecystitis

See Acute Cholecystitis algorithm below, Appendix 2

- 1) Technologist will verify the patient prep of NPO status and when/what they last ate. Also verify what opiates they are on and when the last dose was given. The Faculty or Resident will as well verify NPO and opiate status including can morphine if needed be administered on top of current opioids.
  - a) NM Faculty or Resident will determine if pre-treatment with Sincalide is needed and place the IP order.
  - b) If pre-treatment is given imaging cannot start earlier than 15-60 minutes post the completion of the 30 minute Sincalide infusion.
- 2) Position patient supine under the camera.
- 3) Image immediately post injection

## Division of Nuclear Medicine Procedure / Protocol University Hospital and The American Center

- 4) Dynamic Acquisition in the anterior projection unless otherwise indicated:
  - a) 1<sup>st</sup> Set: 1 min/frame x 30 min, 128 x 128, 1.0 zoom, 20% window peaked for 99mTc. Start acquisition at injection. Label the image set: **Anterior 0-30 minutes**.
  - b) 2<sup>nd</sup> Set: 1 min/frame x 90 min, 128 x 128, 1.0 zoom, 20% window peaked for 99mTc. Start at the end of 1<sup>st</sup> set. This set can be stopped 30-60 minutes post morphine or when gall bladder is visualized. Label the image set: **Anterior 30-90 minutes**. Adjust "90" as needed afterwards based on actual study timing.
- 5) **Evaluate with NM faculty/resident at 30 minutes:**
  - a) Is there sufficient hepatocyte function? (Blood pool clearance from the heart). If no, consider 24 hour delayed imaging.
  - b) Is there common bile duct and duodenum visualize, but the gallbladder does not, consider morphine or delayed imaging.
    - i) If morphine is indicated:
      - (1) Obtain patient weight in kg and calculate dose at 0.04 milligram/kg. Use larger doses of morphine in acute acalculous cholecystitis (requires faculty approval).
      - (2) The NM Faculty or Resident or Nuclear Medicine technologist is to slowly administer the morphine over a 2-minute period at 40 minutes post radiopharmaceutical injection. If this administration is later than 40 minutes consider an additional half dose 99mTc-Mebrofenin, based on the original dose, before the morphine administration.
        - (a) The duodenum should demonstrate decreased and changing activity to confirm the sphincter of Oddi has contracted.
        - (b) Gastric reflux often occurs in about 60% of patients with morphine.
        - (c) The sedation policy does not apply to this diagnostic use of IV morphine. See disclaimer above.
      - (3) Continue imaging to 30-60 minutes post morphine or until the gallbladder is visualized.
    - ii) If delayed imaging is indicated: Image at 2 hours and 3 to 4 hours post injection.
  - b) If these views do not confirm the gallbladder
- 6) Once the gallbladder is believed to be visualized confirm with a Right lateral (or steep RAO if the lateral is not obtainable) and LAO views with 5 minute statics in a 128x128 matrix. Image labels include the time post 99mTc-Mebrofenin injection. i.e. Rt Lat 30 min. The technologist can take these views as a part of the evaluation in point 5 above if they feel the gallbladder is filling.
  - a) If these views confirm gallbladder, imaging is complete.
  - b) If these views do not confirm the gallbladder
    - i) Set up and start another 1 min/frame x 90 min, 128 x 128, 1.0 zoom, 20% window peaked for 99mTc. Label the image set: **Anterior xx-yy minutes**. Adjust "xx and yy" as needed afterwards based on actual study timing.
    - ii) Return to point 5 above if morphine or delayed imaging has not been done. If both have been done, at the discretion of the NM Faculty/Resident the exam is likely complete with an Acute Cholecystis result.

## Division of Nuclear Medicine Procedure / Protocol University Hospital and The American Center

### GBEF (Gallbladder Ejection Fraction) with Sincalide

- 1) Place an IV (per hospital policy).
- 2) Check availability of camera with imaging technologist.
- 3) Inject the patient with 99mTc Mebrofenin via IV push.
- 4) Sincalide Infusion Imaging Parameters
  - a) Imaging should be started 45 minutes post injection.
  - b) Dynamic acquisition 1 min/frame x 65 frames, 128 x 128, 1.0 zoom, 20% window peaked for 99mTc,
  - c) **CHECK POSITIONING WITH NUC MED PHYSICIAN DURING THE FIRST 5-MIN OF THE DYNAMIC ACQUISITION BEFORE ADMINISTERING SINCALIDE. ADMINISTER SINCALIDE IF:**
    - Most of the activity is in the gallbladder and bowel with relatively little in the liver.
    - Ensure the gallbladder is separated from the duodenum by utilizing the LAO view, if necessary.
    - NM Faculty or Resident could ask for a delay in starting the Sincalide infusion. Another pre-infusion imaging set will be required. Exam could also be canceled if the gallbladder does not fill sufficiently.
  - d) Sincalide administration is typically 50-60 minutes post 99mTc Mebrofenin injection.
  - e) Sincalide is infused over 60 minutes. Imaging is complete when the Sincalide infusion is complete.

### GBEF (Gallbladder Ejection Fraction) with 8 fl. oz. (240 mL) of Ensure Plus®

- 1) Place an IV (per hospital policy).
- 2) Check availability of camera with imaging technologist.
- 3) Inject the patient with 99mTc Mebrofenin via IV push.
- 4) Pre-Ensure Plus Imaging Parameters.
  - a) Imaging should be performed 45 minutes post injection.
  - b) Dynamic acquisition 1 min/frame x 5 frames, 128 x 128, 1.0 zoom, 20% window peaked for 99mTc.
  - c) Check images to ensure GB is not over the duodenum, and if so, use LAO view to separate GB from duodenum.
  - d) **CHECK WITH NUC MED PHYSICIAN AT COMPLETION OF 5-MIN DYNAMIC BEFORE PROCEEDING FURTHER. ALLOW DRINKING OF 8 fl. oz of Ensure Plus® IF:**
    - Most of the activity is in the gallbladder and bowel with relatively little in the liver.
    - Verify the gallbladder is separated from the duodenum by utilizing the LAO view, if necessary.
- 5) Post-Ensure Plus Imaging Parameters.
  - a) Have patient drink one entire bottle of 8 fl oz of **Ensure Plus® within 2-3 minutes.**
  - b) Immediately post-Ensure, start a new dynamic acquisition 1 min/frame x 60 frames, 128x128, 1.0 zoom, 20% window peaked for 99mTc.

### Leak

1. Position patient supine under camera.
2. Image immediately after injection.
3. Dynamic acquisition 1 min/frame x 60 frames, 128 x 128, 1.0 zoom, 20% window peaked for 99mTc.
  - a. If the patient has a drainage bag
    - i. Do your best to get it into the field of view free of body structures.
    - ii. If unable to image the drainage bag free of body structures then image bag after the 60 minute dynamic by placing lead under the drainage bag and acquire two static images 256x256, for 5 minutes, 1.0 zoom. Image one is the bag itself. Image 2 using a point source mark the top, bottom and sides of the drainage bag.
    - iii. At interpreter request a Right Lateral Decubitus and Right lateral. 256x256, for 5 minutes, 1.0 zoom.
4. Delayed images at 2-4 hours will usually be necessary and 24 hour delayed images may be needed.

## Division of Nuclear Medicine Procedure / Protocol University Hospital and The American Center

### Hepatobiliary for Sphincter of Oddi dysfunction with Sincalide

1. Place an IV (per hospital policy).
2. Infuse the patient with Sincalide over 30 minutes as described above.
3. Anterior projection imaging should be started 10-60 minutes post Sincalide infusion. Dynamic acquisition 1 min/frame x 60 frames, 128 x 128, 1.0 zoom, 20% window peaked for 99mTc.
4. Process the ROI and generate time-activity curves post imaging. See data analysis below.
5. Check images and data generation with the reading room prior to releasing the patient.

**Comments:** A Nuclear Medicine staff or resident physician should be consulted to determine if additional views are indicated.

### **Data Analysis:**

#### Acute Cholecystitis

- Combine all sequentially acquired dynamic images into one dynamic.
- Reframed combined dynamic and any other later dynamic into 5 minute/frame image sets.
- Screen cap reframed 5 minute/frame image sets
  - ◆ Annotate - view/projection, orientation, 2<sup>nd</sup> 99mTc-Mebrofenin dose if given, morphine injection time and time delay between images sets.
  - ◆ Screen Cap label - add to the front of the screen cap label: **Anterior 0-xx minutes.**
- Screen cap static images
  - ◆ Annotate view/projection, orientation, time reference post initial 99mTc-Mebrofenin injection.

#### GBEF (Gallbladder Ejection Fraction)

Prior to analysis of GBEF perform motion correction.

Analyze with the GE Protocol UWH Gallbladder EF. On the GB composite image the GB ROI is drawn around the gallbladder and the BKGD ROI is drawn to include a segment of the liver and body background. When drawing the ROI's other liver abdominal anatomy is not to be in the region (e.g. bowel or bile ducts). The application uses these ROI's to create a Bkgd corrected GB emptying curve.

The application then selects the frame with the highest counts and uses that to calculate the EF. Verify and adjust the cursor placement as follows; peak activity (green cursor) and nadir/least activity (yellow cursor) are correctly placed on the GB emptying curve then create Dynamic Screen Capture this GBEF result page. Note: This screen cap includes the 1 minute dynamic image set with the ROI that can be cined in PACS.

#### ***CHECK for any bowel and outside activity interference.***

Do a cine review of the dynamic images with the ROI and check for bowel or other activity entering the ROI that is not gallbladder. If there is extra activity, redraw the ROI to eliminate this extra activity. Extra activity causes an error in the GBEF calculation.

- 1) Reframed dynamic image set into 5 minute/frame image set.
- 2) Screen cap reframed 5 minute/frame image sets
  - a) Annotate - view/projection, orientation
  - b) Screen Cap label - add to the front of the screen cap label: **Anterior 0-xx minutes.**
- 3) Screen cap static images
  - a) Annotate view/projection, orientation, time reference post initial 99mTc-Mebrofenin injection.

## Division of Nuclear Medicine Procedure / Protocol University Hospital and The American Center

### Sphincter of Oddi Dysfunction (SOD)

Prior to analysis check raw images to determine if the Motion Correction program needs to be performed.

- 1) Use the predefined ROI Comparative Analysis protocol
- 2) Combine 1 min/frame into one 60 min image.
- 3) Draw a region of interest around the right lobe of the liver and one around the common bile duct. Make sure these ROIs do not overlap the small bowel or liver. (Check with physician if hard to define proper ROI)
- 4) Draw a background ROI
- 5) Take the right lobe ROI and subtract the background ROI, create a time activity curve.
- 6) Take the common bile duct ROI and subtract the background ROI, create a time activity curve.
- 7) Properly annotate each ROI and SCREENCAP
- 8) Reframe the dynamic image set into 5 minute/frame image sets and screen cap as a 12 on one display.
  - a) Annotate - view/projection, orientation
  - b) Screen Cap label - add to the front of the screen cap label: **ANT 0-60 minutes.**

### LEAK

- 1) Reframed dynamic image set into 5 minute/frame image set.
- 2) Screen cap reframed 5 minute/frame image sets
  - a) Annotate - view/projection, orientation
  - b) Screen Cap label - add to the front of the screen cap label: **Anterior 0-xx minutes.**
- 3) Screen cap static images
  - a) Annotate view/projection, orientation, time reference post initial 99mTc-Mebrofenin injection.

### **PACS:**

#### Acute Cholecystitis or Leak

- Send all 1-minute dynamic datasets
- Send all reframed dynamic datasets
- Send all static images
- Send all Screen Caps
- Using paper scanner scan in the worksheet.

#### GBEF (Gallbladder Ejection Fraction) or Sphincter of Oddi Dysfunction (SOD)

- Send all 1-minute dynamic datasets
- Send all reframed 5-minute dynamic datasets
- Send all Screen Caps
- Send the data generated images (automatic GBEF result page, SOD time-activity curves).
- Using paper scanner scan in the worksheet.

### **Interpretation:**

Non-visualization of the gallbladder suggests obstruction of the cystic duct and this is the nuclear medicine physiological requirement of acute calculous or acalculous cholecystitis. In acalculous cholecystitis the cystic duct can be patent resulting in a false negative test.

The gallbladder is normally visualized by 10-15 minutes, somewhat slower in the post-prandial state. Reflux of tracer into the stomach frequently indicates gastric disorder but is common in normal patients.

If there is poor visualization of the intrahepatic biliary ducts or delayed blood clearance, then hepatocyte dysfunction is likely, and the bilirubin should be reviewed. When there is hepatocyte dysfunction, delayed imaging is often needed.

## Division of Nuclear Medicine Procedure / Protocol University Hospital and The American Center

When using morphine, watch for emptying of the duodenum as evidence of spasm of sphincter of Oddi. This is required to raise intra-CBD pressure and therefore fill the gallbladder in chronic cholecystitis and possibly acalculous cholecystitis.

The hepatobiliary scan can actually diagnose obstruction of the CBD prior to US (but this will only occur in first 4 or 5 days). Image for 60 min and then obtain delayed view (4-5 hours). With obstruction, the development of raised intra-CBD pressure occurs, and as this increases and becomes persistent, CBD dilatation occurs. US detection is then very sensitive. With this passage of time there becomes back-pressure on the hepatocyte so that the biliary tract is no longer visualized on our scan, but then hepatocyte dysfunction is documented by delayed plasma clearance of tracer.

In biliary dyskinesia, ensure that patient movement and non-gallbladder tracer do not move out of the ROI used to calculate EF. Tight regions should be created about the gallbladder at the start of the CCK-8 infusion (or Ensure). Without attention to this detail, many false negative and positive scans will occur. The GBEF should be measured with background subtraction and the background should represent contaminating activities (e.g., liver and bowel). The true highest and lowest counts are used if they differ from the automatic calculations. Normal GBEF for our institution is  $\geq 38\%$

In biliary atresia, there is minor urinary excretion (more with Disofenin than Mebrofenin), but no gastrointestinal tract excretion. Severe neonatal hepatitis can emulate biliary atresia but pre-administration of Phenobarbital results in increased hepatobiliary excretion and so separates these two conditions.

In patients with a possible Sphincter of Oddi Dysfunction (SOD), a numerical score should be reported in the interpretation (SOD score > 5 is abnormal).

**Table: Sostre Criteria for Scoring Scintigrams**

All patients with normal sphincter had scores of 0-4. Patients with SOD had values of 5-12

Criteria Score		
1.	1. Peak time	
	a. < 10 min	0
	b. 10 min	1
2.	Time of biliary visualization	
	a. < 15 min	0
	b. $\geq 15$ min	1
3.	Prominence of biliary tree	
	a. Not prominent	0
	b. Prominent major hepatic ducts	1
	c. Prominent small hepatic ducts	2
4.	Bowel visualization	
	a. < 15 min	0
	b. 15-30 min	1
	c. > 30 min	2
5.	CBD emptying	
	a. > 50%	0
	b. < 50%	1
	c. No change	2
	d. Shows increasing activity	3
6.	CBD-to-liver ratio	
	a. $\text{CBD (60min)} \leq \text{Liver (60min)}$	0
	b. $\text{Liver (60min)} < \text{CBD (60min)} < \text{Liver (15min)}$	1
	c. $\text{Liver (60min)} < \text{CBD (60min)} = \text{Liver (15min)}$	2



## Division of Nuclear Medicine Procedure / Protocol University Hospital and The American Center

d. Liver (60min) < Liver (15min) < CBD (60min) 3

**Appendices:**

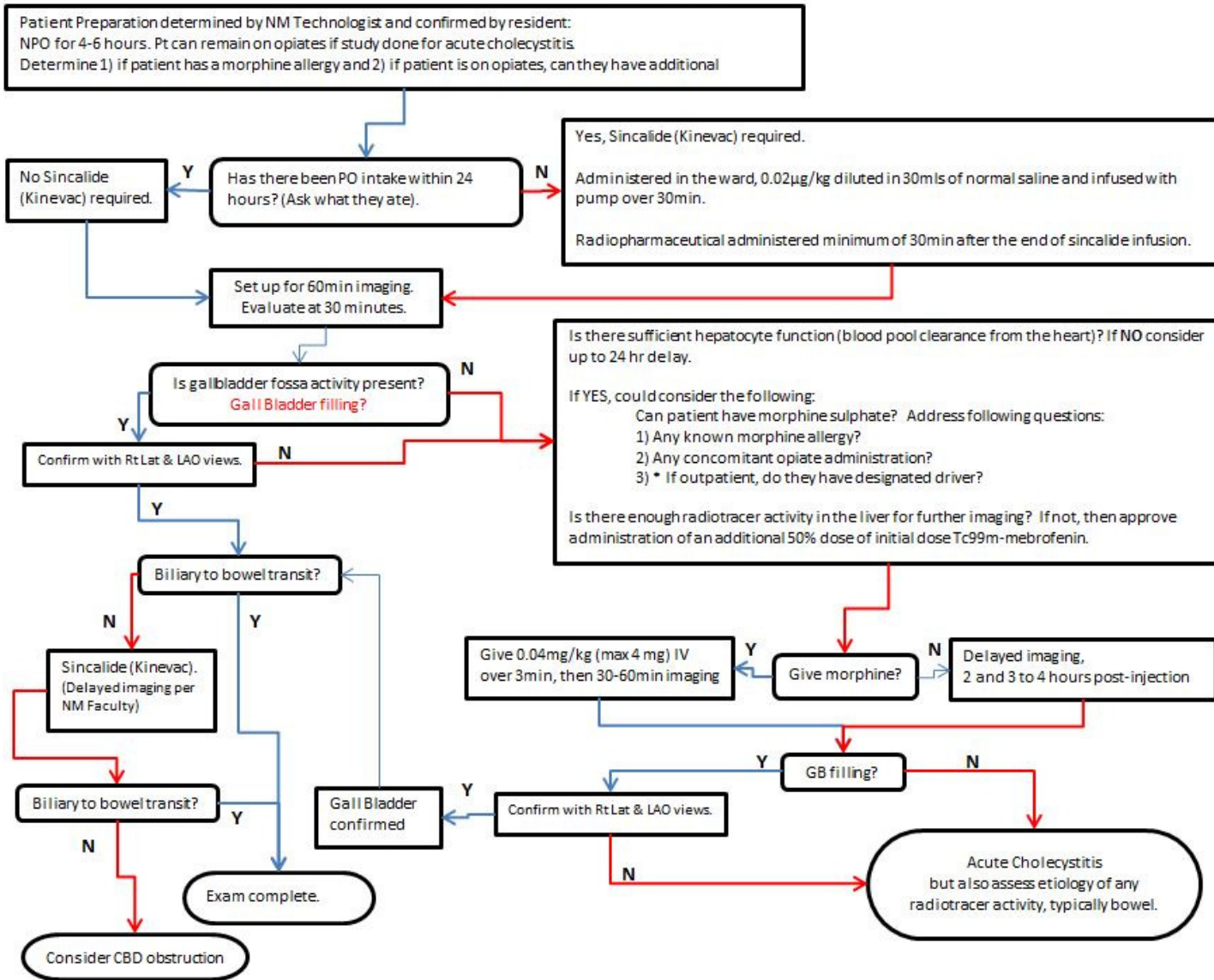
**Appendix 1: OPIOD REFERENCE TABLE FOR HEPATOBILIARY SCANNING**

Drug	T ½ (hrs) Immediate Release	T ½ (hrs) Extended Release	5 t ½'s (hrs) Immediate Release	5 t ½'s (hrs) Extended Release
Morphine (Kadian, MS Contin-ER preps) IV, PO	2-4	12	10-20	60
Hydromorphone (Dilaudid-IR prep, Exalgo-ER prep) IV, PO	2-3	11	10-15	55
Codeine PO	2.5-3.5		12.5-17.5	
Oxycodone IR prep, oxycontin-ER prep PO	3-4	4.5-5.5	15-20	22.5-27.5
Hydrocodone norco) PO	3.3-4.4		16.5-22	
Meperidine (Demerol) IV, PO	2.5-4 7-11 in liver dz		12.5-20 35-55 in liver dz	
Fentanyl (Duragesic) IV, topical, lozenge	20-27 (patch) 2-4 (IV)		100-135 (patch) 10-20 (IV)	

## Division of Nuclear Medicine Procedure / Protocol University Hospital and The American Center

### Appendix 2

#### ACUTE CALCULOUS CHOLECYSTITIS ALGORITHM



## Division of Nuclear Medicine Procedure / Protocol University Hospital and The American Center

### References:

1. Hepatobiliary Imaging - Sphincter of Oddi Dysfunction, THE JOHNS HOPKINS HOSPITAL DEPARTMENT OF RADIOLOGY AND RADIOLOGICAL SCIENCE POLICY/PROCEDURE MANUAL NUCLEAR MEDICINE, 11-03-2011
2. SNM Practice Guideline for Hepatobiliary Scintigraphy 4.0\*, JOURNAL OF NUCLEAR MEDICINE TECHNOLOGY • Vol. 38 • No. 4 • December 2010

---

Reviewed By:

Group review by the Nuclear Medicine Faculty, Residents and Technologists

---

Scott B. Perlman, MD, MS  
Chief, Nuclear Medicine

---

Derek Fuerbringer, CNMT  
Manager, Nuclear Medicine  
University Hospital

---

Kandace Nowakowski  
Manager, Nuclear Medicine  
The American Center

---

Scott Knishka, RPh, BCNP  
Radiopharmacist

---

John Vetter, PhD, DABR  
Medical Physicist