

Musculoskeletal Imaging and Intervention Section Imaging Procedures

SI Joint Injection

INDICATIONS

Pain in a specific region of the medial buttocks.

RISKS

- Allergic reaction to contrast
- Hematoma
- Infection
- Pain
- Transient lower extremity numbness or weakness

MATERIALS

- C-Arm
- 4 x 4 gauze
- Alcohol
- Betadine
- 3 cc syringe
- 1 cc syringe
- 10 cc syringe
- Small extension tubing
- 1% lidocaine buffered for local anesthesia
- Contrast material
- 22G spinal needle with 10° curved tip
- Steridrape
- Solution of 1 cc 0.5% Bupivacaine without preservative mixed with 1 cc of Celestone or Kenalog

TECHNIQUE

1. Review the patient's cross sectional imaging studies to try and estimate the best angle to approach the posterior aspect of the patient's sacroiliac joint.
2. Place patient prone.
3. With tube straight, mark on skin over the inferior margin of the SI joint.
4. Then angle the tube toward the head and medial or lateral as necessary until the inferior portion of the SI joint is clearly seen and aligned (25°-35°). Save this position.
5. Anesthetize where the skin was marked with 25G 3½" needle down to the bone by putting the needle nearly straight but with a slight cephalad angulation.
6. Insert the 22G 3 ½" needle nearly straight but angle the tip just slightly cephalad

7. Walk the needle toward the joint. You should feel the needle wedge or fall into the joint (Figure 2).




Fig 2: SI joint needle approach, AP.

8. Using a 1 cc medallion syringe, inject a small amount of contrast to confirm the position. A 1 cc syringe is used because it often takes relatively high pressure to access the joint (Figure 3).

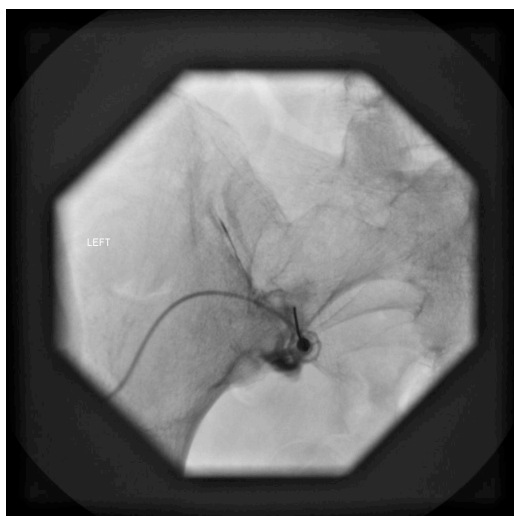


Fig 3: Contrast injection confirming needle position in SI joint, AP.

9. Take film.
10. With a 3 cc syringe, inject 1cc of Kenalog mixed with 1 cc 0.5% Bupivacaine (2 cc total).

PITFALLS

If you are not in the joint, avoid injecting too much contrast over the joint. This can obscure the joint and make it difficult to visualize landmarks needed to redirect the needle.