

Musculoskeletal Imaging and Intervention Section Imaging Procedures

Imaging Procedures **Intraarticular Facet Injections**

LUMBAR FACET INJECTIONS INDICATIONS

- Facet syndrome – uncommon
- Clinical diagnosis – point tenderness over facets, pain with hyperextension
- Diagnostic injection – pain relief with a non-ruptured facet joint injection

RISKS

- Hematoma
- Infection
- Transient paralysis

PREREQUISITES

- Must have AP and lateral plain films of the spine. Fluoro to obtain otherwise.
- Preprocedure cross sectional imaging preferred.
- Explain procedure to patient.
- Obtained signed consent.

MATERIALS

- Alcohol, betadine
- Steridrape
- 5 cc syringe for anesthetic
- 3 cc syringe for contrast
- 3 cc syringe for steroid/anesthesia
- Omnipaque 300 (3 cc)
- 25G 1½" needle
- 0.5 cc 8.4% Na Bicarb
- 1% Lidocaine MPF
- 0.5% Bupivacaine MPF (1 cc)
- Celestone (6 mg) 1 cc
- 25G 3½" spinal needle

TECHNIQUE

1. Position the patient prone with a pillow under the abdomen to straighten the spine.
2. Profile the disk at the appropriate level.
3. There are two targets which can be used for a lumbar intraarticular facet injection:

- a. The standard approach: Off your preprocedure cross sectional study, estimate the ideal angle of entry to the most posterior portion of the midpoint of the facet joint. The most posterior portion of the joint is often the first portion seen as the tube is rolled oblique from the AP view. Aim for the midportion of the facet joint. Once the 22 G, 3.5 inch spinal needle is in position, work the needle around until you feel it fall into the joint (Figure 1).

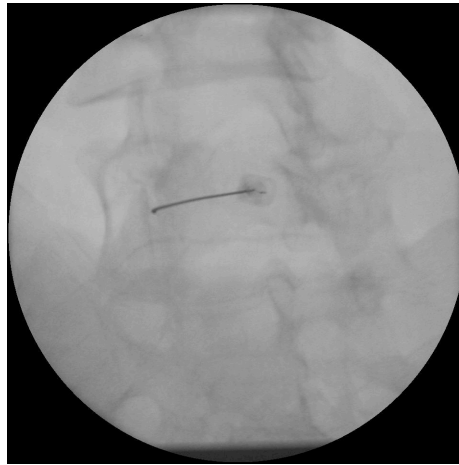

Fig 1: Facet needle positioning, oblique

- b. Other institutions advocate aiming for the inferior recess of the facet joint. Oblique the tube to the Scottie dog view. Aim for the inferomedial aspect of the facet joint.
4. If an intraarticular injection is attempted but it is not possible to enter the facet joint, a perifacet injection can be performed at the same spot.

Fig. 1: Spinal Nerve	Fig. 2: Facet Nerve Block
A - Anterior Branch	A - Sites of intraarticular injection
B - Posterior Branch	B - Site of perifacet injection

5. When the needles in proper position by fluoroscopy, inject a small amount (up to 0.5 cc) of non-ionic contrast material (Omnipaque 300) to document intraarticular positioning and save an image. It is often helpful to use a 1 cc medallion syringe to generate the pressure needed to inject contrast into the very tight and often degenerated facet joint. Take care not to inject too much contrast at one time as it can obscure the joint, making it difficult to document intraarticular placement if you need to reposition (Figure 2).

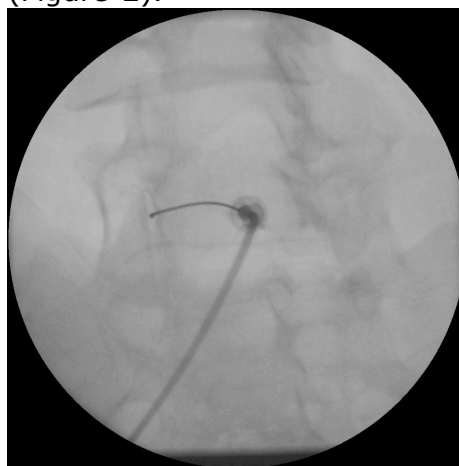


Fig 2: Facet injection, oblique

6. The capacity of a normal facet joint is approximately 1.5 cc. After confirming intraarticular placement with up to 0.5 cc Omnipaque 300, inject 1.0 cc of a mix of 0.5 cc Bupivacaine 0.5% with 0.5 cc (6 mg) Celestone.

THORACIC INTRAARTICULAR FACET INJECTIONS BACKGROUND/ANATOMY

Thoracic facet joints are oriented at about 60° to the horizontal and rotated 20° in a medial direction. The lateral aspect of the joint is located anteriorly whereas the medial side of the joint is located more posteriorly. The lower thoracic facet joints resemble more the lumbar facets with the joints oriented sagittally.

Referred pain patterns are less frequent than in the cervical or lumbar segments. Pain is usually from the level of the affected facet or from one level below. Referred pain may also occur along the rib at the level of the abnormal facet joint, both anteriorly and posteriorly in the chest; however, the pain is usually well localized over the facet joint that is abnormal. Inject the joint suspected of causing the pain and one level above this.

MATERIALS

- Alcohol, betadine
- Steridrape
- 5 cc syringe for anesthetic
- 3 cc syringe for contrast
- 3 cc syringe for steroid/anesthesia
- Omnipaque 300 (3 cc)
- 25G 1 ½" needle
- ½ cc 8.4% Na Bicarb
- 1% lidocaine
- 0.5% Bupivacaine MPF (1 cc)
- Celestone (6 mg) 1 cc
- 25G 3 ½" spinal needle

TECHNIQUE

1. For 2 joints to be injected, draw up 1 cc of Bupivacaine and 1 cc of Celestone in a syringe (2 cc total) and distribute about ½ cc to each joint. The patient is to be placed prone on the table, skin prep and sterile drape as usual. Anesthetize with buffered lidocaine.
2. Align vertebral endplates. Mark skin over the mid to inferior pedicle of the level below the target joint (example: the inferior margin of the T7-8 facet joint is superimposed over the superior portion of the pedicle of the T-8 vertebra. The skin site to be marked for starting the needle is the mid to inferior portion of the T-9 pedicle one level below the T7-8 facet joint).
3. After skin anesthesia, insert the 3 ½" 25G needle at about a 60° angle toward the head (toward the pedicle and target joint one level above skin entry point). Advance cephalad toward the target joint, keeping the needle aligned between imaginary vertical lines formed by the medial and lateral aspects of the pedicles (this assures that the needle is not too lateral in the lung, or too medial in the epidural space or thecal sac). Since the medial aspect of the joint is more posterior and superficial, aiming for the mid to medial aspect of the joint may facilitate joint entry.

4. Advance the needle about 5 cm until it lies at about the inferior to mid portion of the pedicle one level above the needle entry site (in the example used above, the needle tip should be near the T-8 pedicle).
5. Angle the image intensifier away from the side being injected until the joint is seen well aligned (nearly lateral position of the tube). The needle should be seen near the inferior aspect of the target joint and then inserted directly into the joint without moving the needle in a medial or lateral direction.
6. Confirm proper needle position by injecting a drop of contrast material. The joint has a total capacity of about ½ cc, so, do not put much contrast in. Inject ½ cc of the mixture of 0.5% Bupivacaine with Celestone.
7. Document pain provocation and any pain relief. Make sure no difficulty with breathing (pneumothorax).

TECHNIQUE (More T-Spine Facet Information)

1. Review plain film/MRI/CT studies.
2. Obtain signed consent.
3. Position the patient prone.
4. Mark the levels to be injected – always inject two adjacent levels. It is almost impossible to go intraarticular, so aim for the extraarticular medial branch of the dorsal ramus. Aim for the junction of the transverse process with the superior facet for T11-12. See figure 1. The nerve lies more lateral on the upper margin of the transverse process from C8 to T10, and the • in Figure 1 marks the site for extraarticular injection for C8 to T10.
5. When the needle is in proper position by fluoroscopy, inject a drop of non-ionic contrast (Omnipaque 300) to document facet or peri-facet location. Take the spot film.
6. At each level inject 1.0 cc of a solution containing Bupivacaine and Celestone. Solution is obtained by mixing 1 cc of Bupivacaine (0.5%) with 1 cc Celestone (6 mg).

CERVICAL FACET INJECTIONS RISKS

- Pain
- Bleeding
- Numbness
- Paralysis (usually transient)

TECHNIQUE

1. Obtained signed consent.
2. Position patient prone with pillow under the chest and a small pad for the head. The head should be turned AWAY from the side to be injected and flexed. If right-sided facets are to be injected, the head is to be turned to the left.
3. Angle the tower cephalad to show the facet joint tangential to the x-ray beam. When the facet joints are shown in proper position, mark the puncture site with wire loop at the lateral and inferior aspects of the joint (see diagram). Always inject at least two adjacent levels.
4. Prep and drape as for all procedures: 1 alcohol, 3 betadine, steridrape.
5. Anesthetize (lidocaine 1% preservative free) the skin with a 25G needle.
6. Insert 22 or 25G 3 ½" spinal needle into the lateral aspect of the facet joint.

7. Document the position of the needle tip by injecting a drop of Omnipaque 300 and take a film. Whether the intraarticular or perifacet is in location is not as important as assuring that the needle is not in a vessel or nerve root sheath, subarachnoid space, etc.
8. For two joints, mix up a solution of 1.0 cc of 1% preservative free Lidocaine and 1.0 cc of Celestone (6 mg). **Bupivacaine is not used** in the cervical spine, because if it gets into the subarachnoid space respiratory difficulties may occur and will last much longer than those from Lidocaine.
9. Inject 1 cc of the mixture Lidocaine/Celestone at each of the sites.