



## **Musculoskeletal Imaging and Intervention Section Imaging Procedures**

### **Cervical Nerve Root Block**

#### **INDICATIONS**

- Patients with radicular symptoms in whom:
  - Therapeutic effects are desired (to delay or prevent surgery)
  - Imaging studies are normal
  - Imaging studies show multiple levels of pathology

#### **RISKS**

- Hematoma
- Pain
- Infection
- Nerve damage
- Transient weakness or paralysis
- Injury to carotid or vertebral arteries

#### **PREREQUISITES**

- Patient accompanied by someone to drive home.
- AP and lateral C-spine plain films in last month to exclude infection, tumor, etc.
- Check MRI or myelogram if available.
- Obtain signed consent.

#### **MATERIALS**

- C-Arm Fluoro
- Alcohol, Betadine
- 4 x 4 sponges
- IV hep lock connecting tube
- 5 cc syringe
- 10 cc syringe (2)
- 25G 1½" or 25G 3½" needle
- Steridrape (aperture)
- 1% lidocaine (for skin numbing)
- 0.5% lidocaine without epinephrine, preservative free
- Omnipaque 300
- Celestone 6 mg/cc

#### **TECHNIQUE**

1. Review films, check request, and discuss symptoms with patient to confirm or determine level. When checking the patient's MRI, always identify the vertebral artery at the level to be injected. Be familiar with the anatomy, remember that there are 7 cervical vertebrae and 8 cervical nerves, e.g. if the C5 nerve is to be blocked, aim for

2. Have the patient turn head **AWAY** from symptomatic side. In female patients a hair net may be necessary. Palpate and mark the carotid artery. Place the needle posterior to the sternocleidomastoid to avoid carotid artery.
3. Pick the proper level and neural foramen to localize by counting down from C2. Use a compound angle from the true AP projection to align the neural foramina. Generally, the tube will need to be angled 30-40° toward the side to be injected (Figure 1).

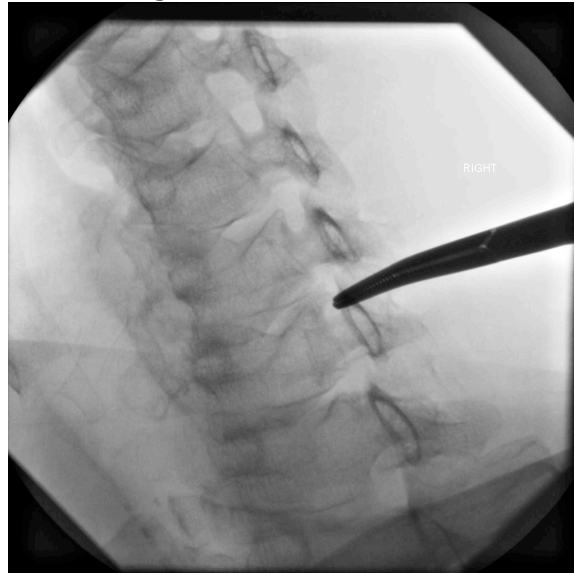

Fig 1: Foramen selection, compound oblique angle.

4. Mark the posterior-inferior corner of the neural foramina to be injected, aiming for the bone on the margin of foramen.
5. Prep the skin, local anesthetic is used sparingly in the deep soft tissues in order to avoid the consequences of infiltration in the cervical epidural space.
6. Choose proper needle. In thinner patients or in the mid to upper C spine, a 1.5 inch 25 gauge needle may be adequate. In larger patients, a 25 g spinal needle may be needed.
7. Advance slowly in the oblique control view with frequent checks in the true AP plane to determine depth. The needle tip should not stray anteriorly or superiorly as this will greatly increase the chances of encountering the vertebral artery.
8. The expected depth of the nerve root to be injected is 2 mm inside the most lateral cortex of the vertebra at this level. Advance to this depth or until the patient reports radicular shoulder or arm pain and the needle tip is in vicinity of the proper depth.
9. Inject a small amount of Omnipaque 300 through the short IV hep lock tubing. The injection should produce a neurogram which runs in an oblique inferolateral direction from the neural foramen. Be cognizant of any vertically oriented or rapidly dissipating contrast that might represent an intravascular injection (Figure 2).

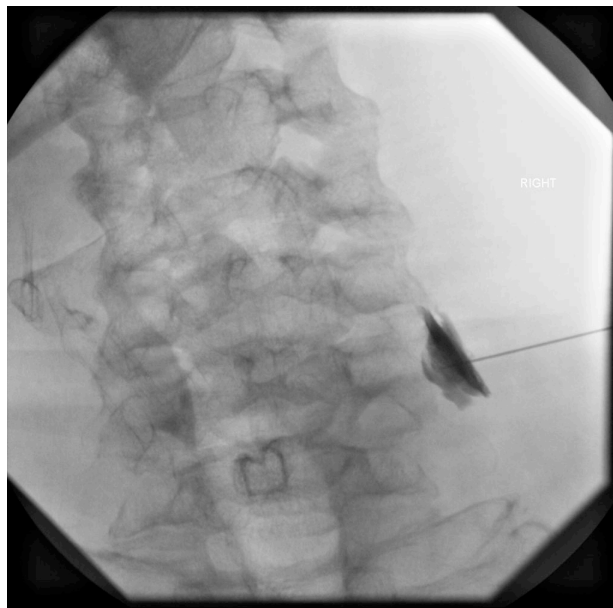


Fig 2: Contrast injection.

10. Disconnect the contrast from the connecting tubing and attach the syringe with the therapeutic solution. The cervical epineural space is the smallest space we inject and this minimizes manipulation of the needle tip during the procedure.
11. If a neurogram was produced, inject 1.0 cc of a 50/50 mixture of Celestone and lidocaine 0.5% without preservatives or epinephrine. If a clear neurogram was not produced on contrast injection, 1.5 cc of the therapeutic solution can be used to flood the area, treating the targeted nerve.
12. Ask if the patient's symptoms have changed in any way, and discuss how to keep a "pain diary" with the patient to present to the referring clinician.

### POTENTIAL PITFALLS

1. **Intraarterial injection: NEVER** inject if there is a possibility of intraarterial injection. There is a risk of stroke because of the particle size of the steroid mix. The needle tip should be incrementally withdrawn until no additional intraarterial injection can be seen. If the needle tip is close enough to the expected position of the nerve root, the therapeutic injection can proceed. The ability to detect intraarterial injection is the strength of fluoroscopy guidance over CT guidance.
2. **Intravenous injection:** If a clear intravenous injection is encountered, the needle must be repositioned. Often withdrawing the needle will result in continued intravenous injections until you are too superficial to inject the targeted cervical nerve root. Often minutely advancing the needle will result in resolution of the intravenous injection and it will be safe to inject the therapeutic solution.
3. **Persistent radicular pain:** The patient will develop transient radicular pain as you approach an inflamed cervical nerve root or as you enter the epineural space. This pain should dissipate over a short time. If the pain persists, it is likely that the needle tip is within the nerve itself, and the needle should be carefully withdrawn in very tiny intervals until the patient's pain subsides.
4. **Early radicular pain:** The nerve roots run very close together after they exit the neural foramen. We have encountered cases where the patient has experienced significant radicular pain with the needle tip superficial to the depth where we would expect to encounter the targeted nerve root. In these circumstances, we typically continue advancing the needle until the tip overlies the most lateral vertebral cortex on the true AP projection and the patient has radicular symptoms.